



C1 ARCH NON-UNION WITH ROTATORY SUBLUXATION

DR.N.AJIT KUMAR

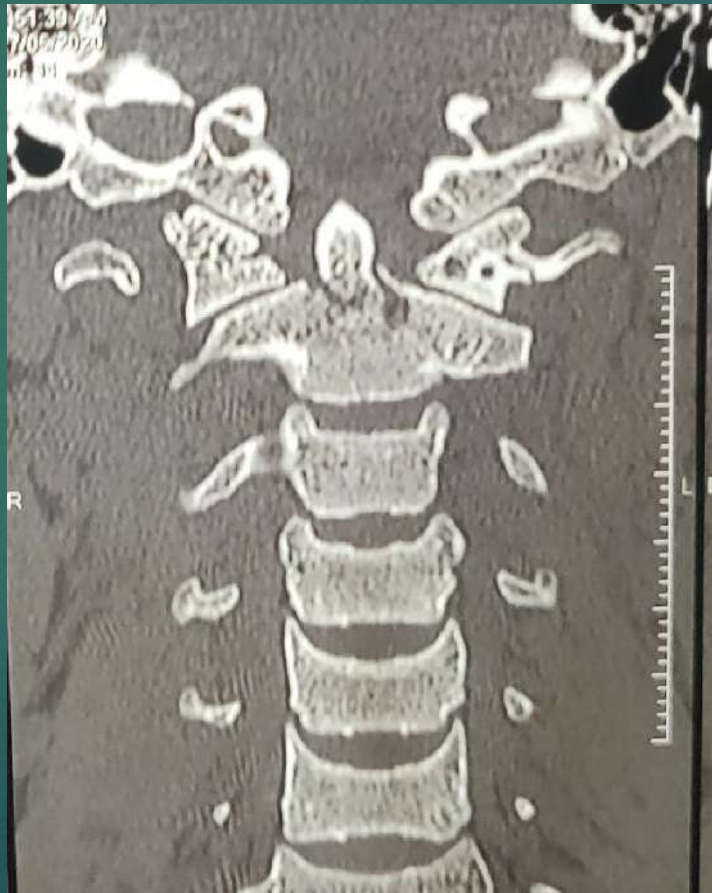ASST PROF ,DEPARTMENT OF ORTHOPAEDICS AND SPINE SURGERY

TRICHY SRM MEDICAL COLLEGE HOSPITAL AND RESEARCH CENTRE

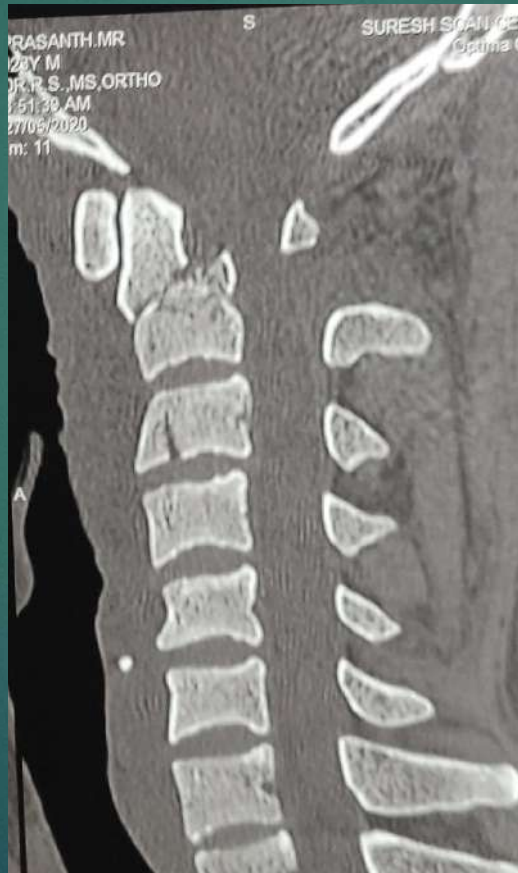Case profile

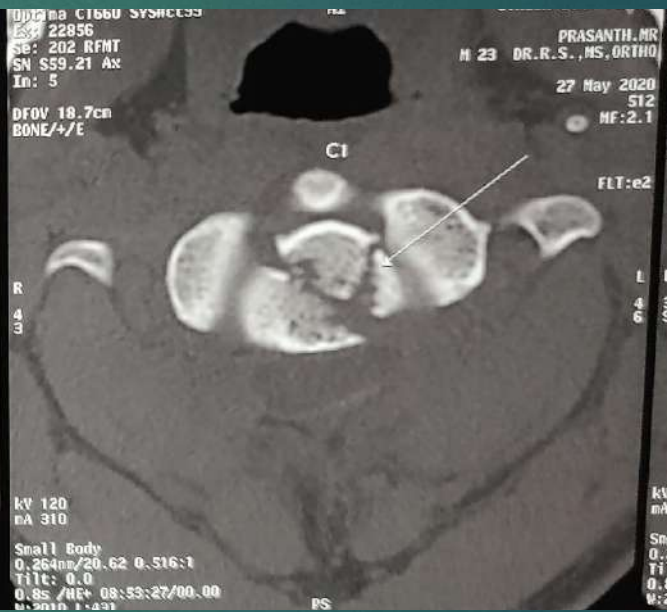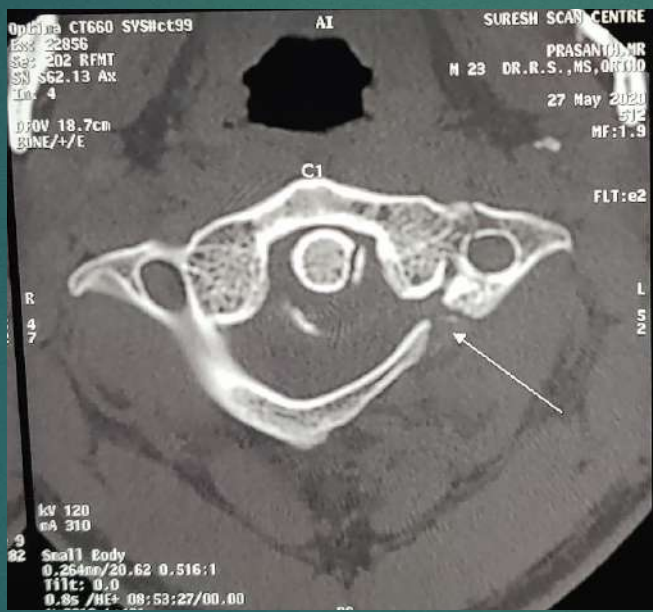- ▶ **Mr.Prashanth 23/M**
- ▶ **Neck pain following RTA**
- ▶ **Type II C odontoid fracture and C3 body fracture**
- ▶ **Normal neurology**

Odontoid fracture

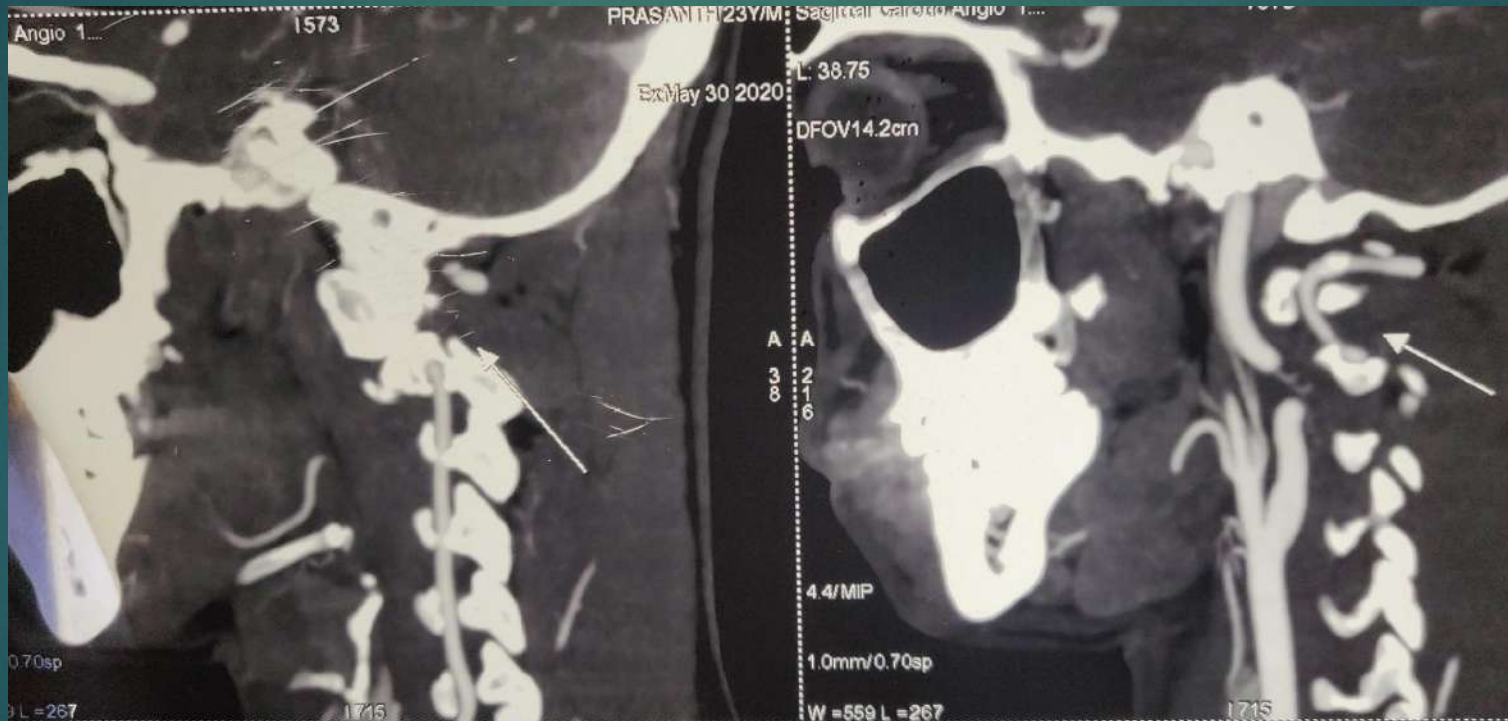


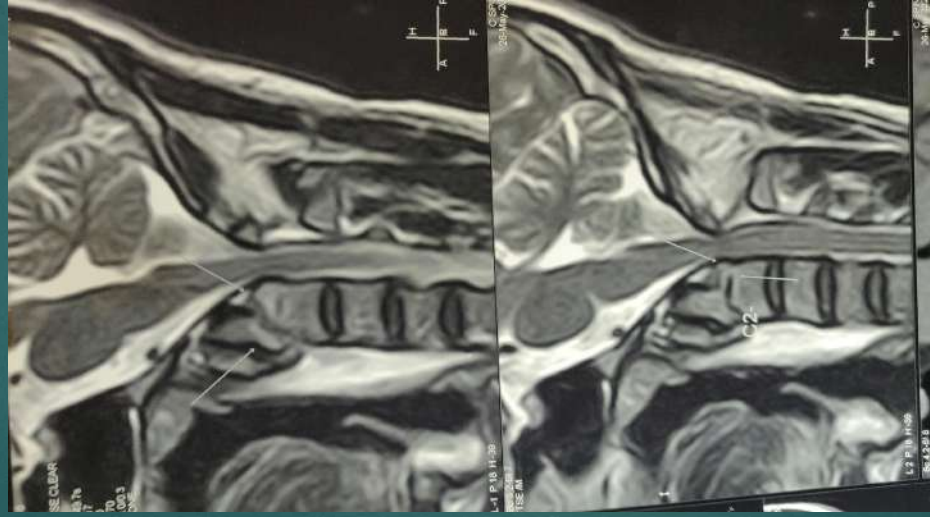
Type II C Odontoid and C3 body fracture



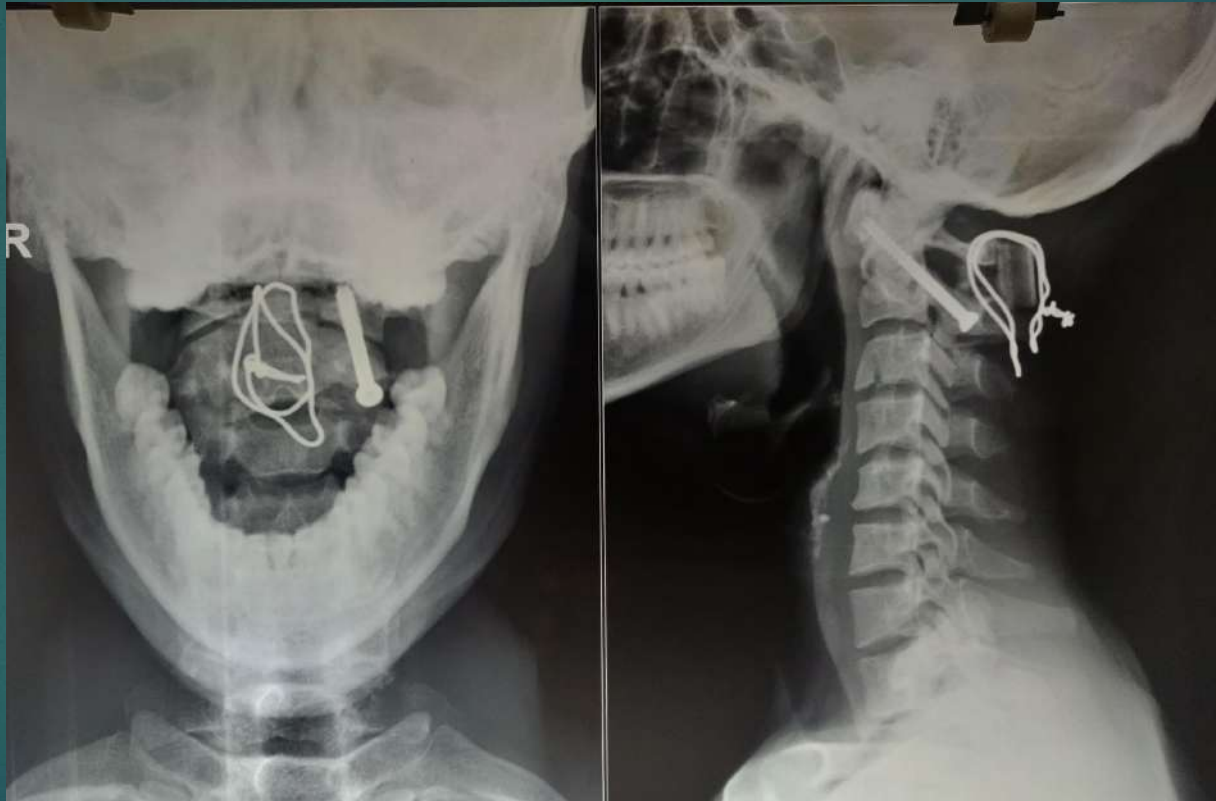

Routine Vertebral artery angiogram prior to C1-C2 instrumentation

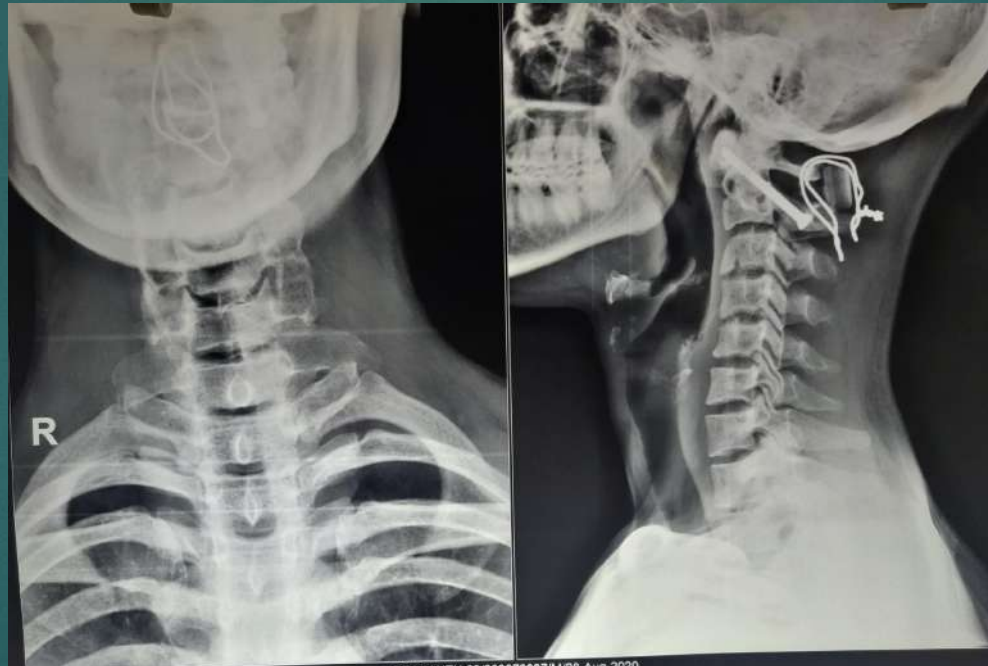



C1-C transarticular screw with posterior wiring and bone graft(July 2020)



August 2020



October 2020

